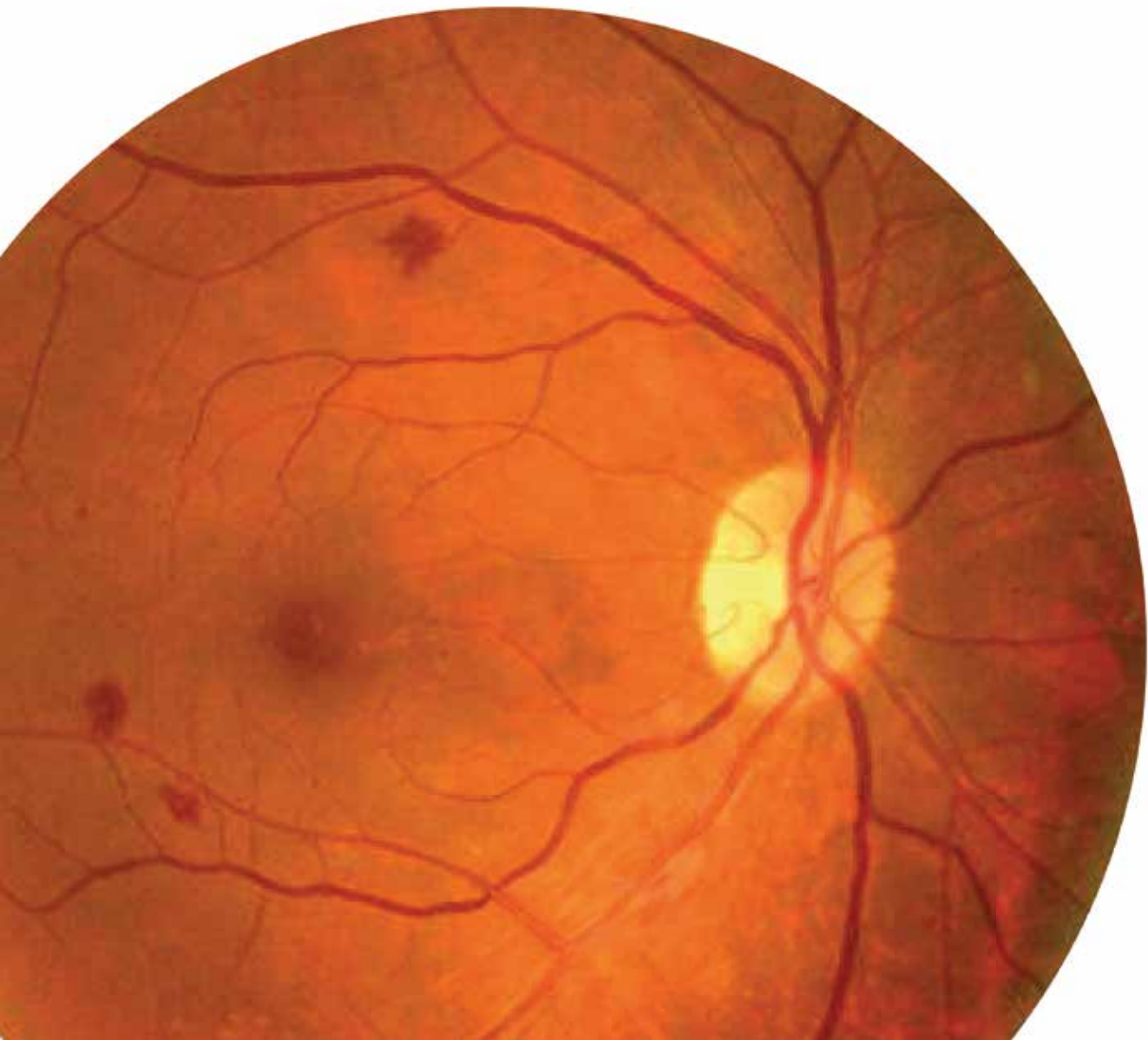



**International
Diabetes
Federation**

Clinical Practice
Recommendations
for Managing

Diabetic Macular Edema





**International
Diabetes
Federation**

Clinical Practice
Recommendations
for Managing

Diabetic Macular Edema

Working group

Chair: Dr Shaukat Sadikot, Jaslok Hospital and Research Centre, Mumbai, India; Diabetes India.

Core contributors:

Prof Anat Lowenstein, Ophthalmology Division, Tel Aviv Medical Center, affiliated with the Sackler Faculty of Medicine, Tel Aviv University, Tel Aviv, Israel.

Prof Gavin Tan, Singapore National Eye Centre & Singapore Eye Research Institute; Eye Academic Clinical Program, Duke-NUS Graduate Medical School, Singapore.

Prof Weiping Jia, Shanghai Diabetes Institute, Shanghai Clinical Center for Diabetes, Shanghai Jiao Tong University Affiliated Sixth People's Hospital, Shanghai, China.

Prof Marco Dutra Medeiros, Department of Ophthalmology – Portuguese Diabetes Association; Department of Ophthalmology – Central Lisbon Hospital Center; NOVA Medical School – Universidade NOVA de Lisboa, Portugal.

Dr Luis Gardete Correia, Associação Protectora dos Diabéticos de Portugal (APDP), Lisbon, Portugal.

Dr Dinah Zur, Ophthalmology Division, Tel Aviv Medical Center, affiliated with the Sackler Faculty of Medicine, Tel Aviv University, Tel Aviv, Israel.

Acknowledgements

- Insignia Learning Pvt. Ltd., India
- IDF Executive Office – Belgium: Belma Malanda; Sameer Pathan; Lisa Duke; Lorenzo Piemonte; Anne Wiebke Ohlrogge; Els Sung

With the support of an international grant from



Duality of interest statement:

All members of the clinical recommendations working group declared dualities of interest in respect of commercial enterprises, governments and non-governmental organisations. No fees were paid to the working group members in connection with the current activity.

Copyright

All rights reserved. No part of this publication may be reproduced or transmitted in any form or by any means without the written prior permission of the IDF. Requests to reproduce or translate IDF publications should be addressed to communications@idf.org

© International Diabetes Federation 2019

Retinal photographs on pages 6, 10, 17, and 19 © International Council of Ophthalmology/ Singapore Eye Research Institute. All rights reserved.

Publisher:

International Diabetes Federation

ISBN: 978-2-930229-91-1

Please cite this report as: International Diabetes Federation. Clinical practice recommendations for managing diabetic macular edema. Brussels, Belgium: International Diabetes Federation, 2019

Correspondence

International Diabetes Federation
166 Chaussée de La Hulpe
B-1170, Brussels
Belgium

communications@idf.org

Table of contents

Foreword	4
1. Introduction to DME	5
1.1 Definition of the problem.....	5
1.2 Classification of DME	5
1.3. Prevalence of DME	6
2. Risk factors for DME	7
2.1 Hyperglycaemia	7
2.2 Hypertension	7
2.3 Dyslipidaemia.....	7
2.4 Duration of diabetes.....	7
2.5 Diabetic retinopathy.....	7
2.6 Obesity	8
2.7 Cataract surgery	8
2.8 Sleep apnoea	8
2.9 Pregnancy	8
3. Screening for DME	10
3.1 Retinal examination	10
3.2 Examination method.....	11
3.3 When to refer to an ophthalmologist.....	14
3.4 Re-examination and referral recommendations.....	14
4. Treatment of DME	16
4.1 Laser photocoagulation.....	17
4.2 Intravitreal injections.....	17
4.3 Polytherapy.....	19
4.4 Surgical approaches.....	19
5. Systemic management of DME	21
6. Patient communication and education	23
Abbreviations	24

Foreword

Diabetes affects an estimated 425 million adults aged between 20 and 79 worldwide. It disproportionately afflicts people in low- and middle-income countries. By 2045, 628 million people, or 1 in 10 adults across the globe, will live with diabetes.

As the numbers increase, more and more people are also living with complications that result directly from diabetes. Some of these are so serious that they are life threatening, while others are sufficiently debilitating to curtail daily activities and quality of life.

Diabetic retinopathy (DR) is a complication of diabetes that may be unnoticeable in its early stages, but which can lead to vision impairment and blindness. It affects an estimated one in three people living with diabetes, and is a primary cause of loss of vision and blindness in those aged between 20 and 65. Chronic hyperglycaemia causes damage to the retinal capillaries, and the risk is exacerbated by hypertension and dyslipidaemia. The vast majority (79%) of respondents with diabetes to *The Diabetes Retinopathy Barometer Report: Global Findings* who had impaired vision due to DR or diabetic macular edema (DME), said their sight problems made everyday activities difficult, and in some cases impossible. These activities included driving, working and cooking or cleaning their home.

DME is a further important complication of diabetes and has unique assessment criteria, since it can present in eyes at all levels of DR. Therefore, early screening and detection is crucial in arresting and where possible correcting DME. Because the early damage is painless and unnoticed by the patient, regular screening of all individuals with diabetes is recommended.

Health practitioners have reported a need for additional training in the diagnosis, treatment and referral of diabetic eye disease. Due to its threat to vision, the clinical signs of DME warrant immediate referral to an ophthalmologist. As such, the employment of trained health care professionals to carry out basic screening and to make appropriate referrals would be the most efficient use of resources.

In support of those on the frontline of diabetic eye health, the International Diabetes Federation (IDF) has led a team of experts in the development of the following clinical practice recommendations for managing diabetic macular edema. This decision support tool will facilitate the work of general practitioners, hospital physicians, and other clinicians who practise in diabetic eye disease management.

These clinical recommendations grew out of a collaborative, evidence-based process. They reflect the latest advances in DME management.

On behalf of the IDF, we would like to thank all the experts, reviewers and editors who have worked to make these recommendations a reality. As a result of their expertise, these clinical practice recommendations are a truly practical guide for clinicians.

These recommendations support clinicians who are caring for their patients with diabetes. We salute their work to protect their patients' vision.

Dr Shaukat Sadikot

Chair of the Working Group

Prof Nam H Cho

IDF President (2018–2019)

1. Introduction to DME

Diabetic macular edema (DME) is a potential complication of diabetic retinopathy (DR). People with diabetes have increased susceptibility to DME.

Increased availability of screening and treatment options for DR and DME offers the possibility of early diagnosis and management, providing opportunities to minimise vision-threatening retinal complications in diabetes. Surveillance and treatment approaches will be informed by the vast numbers of people with diabetes worldwide, as well as the availability, accessibility and affordability of the screening and management strategies for DR and DME. It is important to note that while treatment may be both possible and in principle available, this may not always translate into opportunities for individuals to receive the treatment they require.

These clinical practice recommendations look at the evidence and risk factors, alongside diagnosis, treatment and management strategies, with the aim of alleviating this significant but often neglected health problem.

1.1 Definition of the problem

Physiopathology and the link between DR and DME

DR is a significant complication of diabetes that generally refers to microvascular anomalies in the fundus of the eyes in persons with diabetes. DME involves the deterioration of the blood-retinal barrier in the eye, and a resulting pooling of fluid within the retina's central area. This capillary leakage causes diffuse edema, whereas focal or multifocal leakage from grouped microaneurysms leads to localised edema.

Vascular endothelial growth factor (VEGF) contributes to the pathogenesis of DME, and to a significant increase in vascular permeability. Vitreous VEGF levels are markedly elevated in patients with DME.

Often, DME develops slowly with few overt symptoms. Blurring of the central vision may be the first symptom the patient notices. Severity at diagnosis ranges from mild (a regression of one line on a standardised eye chart) to complete loss of vision.

1.2 Classification of DME

Clinically significant macular edema (CSME) features retinal thickening and/or adjacent hard exudates. Central-involved and non-central-involved macular edema describe the involvement of the centre of the macula or the threat to it.

Diabetic macular edema	Findings observable on dilated ophthalmoscopy*
No DME	No retinal thickening or hard exudates in the macula
Non-central-involved DME	Retinal thickening in the macula that does not involve the central subfield zone and that is 1mm or greater in diameter
Central-involved DME	Retinal thickening in the macula that does involve the central subfield zone that is 1mm or greater in diameter

* Hard exudates indicate either current or previous macular edema. DME is defined as retinal thickening and requires a three-dimensional assessment that is best performed during a dilated examination using slit-lamp biomicroscopy and/or stereo fundus photography.

Central-involved DME refers to the thickening or swelling of the centre of the macula.

Non-central-involved DME indicates the lack of involvement of the centre of the macula.

Focal DME results from microaneurysms that cause internal blood retinal barrier (BRB) damage.

Diffuse DME results from external BRB damage.

Fluorescent angiography (FA) confirms the presence of DME and its classification of focal or diffuse.

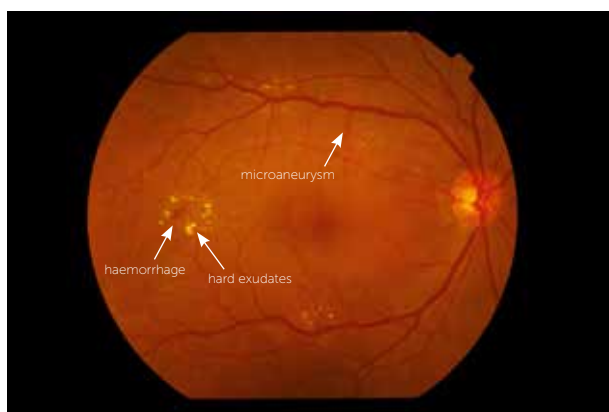


Figure 1. Moderate non-proliferative diabetic retinopathy with haemorrhages, hard exudates and microaneurysms

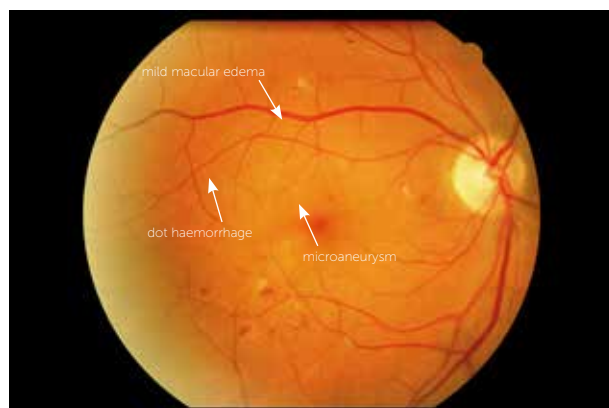


Figure 2. Moderate non-proliferative diabetic retinopathy with mild diabetic macular edema

1.3. Prevalence of DME

The prevalence of DME among those with type 1 diabetes (T1D) and type 2 diabetes (T2D) varies by region. Prevalence rates range from 11% in Europe to 7.5% in some African countries. More than 21 million people are affected worldwide. Approximately one in 14 people with diabetes have some degree of DME.

An estimated 20% of people living with T1D, and 25% of those with T2D, can expect to develop DME. Those diagnosed with proliferative diabetic retinopathy (PDR) are at particular risk for DME.

References

1. International Diabetes Federation. IDF Diabetes Atlas, 8th ed. Brussels, Belgium: International Diabetes Federation, 2017. <http://www.diabetesatlas.org/resources/2017-atlas.html>
2. International Federation on Ageing, International Association for the Prevention of Blindness, International Diabetes Federation. (2015). *The Diabetes Retinopathy Barometer Report: Global Findings*. Retrieved from <https://www.idf.org/our-activities/care-prevention/eye-health/dr-barometer.html>
3. Yau JW, Rogers SL, Kawasaki R, et al. Meta-Analysis for Eye Disease (META-EYE) Study Group. Global prevalence and major risk factors of diabetic retinopathy. *Diabetes Care*. 2012 Mar;35(3):556–64.
4. Lee R, Wong TY, Sabanayagam C, et al. Epidemiology of diabetic retinopathy, diabetic macular edema and related vision loss. *Eye Vis (Lond)*. 2015 Sep 30;2:17.
5. Mavrikakis E, Khan BU, Lam W-C. Macular Edema in Diabetes [Internet] [Medscape 2016]. Available at: <http://emedicine.medscape.com/article/1224138-overview#a6>. Accessed on Aug 19, 2018.
6. Ozaki H, Hayashi H, Vinore SA, et al. Intravitreal sustained release of VEGF causes retinal neovascularization in rabbits and breakdown of the blood-retinal barrier in rabbits and primates. *Exp Eye Res*. 1997 Apr;64(4):505–17.
7. Miyamoto K, Khosrof S, Bursell SE, et al. Vascular endothelial growth factor (VEGF)-induced retinal vascular permeability is mediated by intercellular adhesion molecule-1 (ICAM-1). *Am J Pathol*. 2000 May;156(5):1733–1739.
8. International Council of Ophthalmology. Guidelines for Diabetic Eye Care. Updated 2017. <http://www.icoph.org/downloads/ICOGuidelinesforDiabeticEyeCare.pdf>

2. Risk factors for DME

- Modifiable and non-modifiable risk factors associated with the onset of DME:
 - Hyperglycaemia, especially in the presence of:
 - Hypertension
 - Hyperlipidaemia
 - Longer duration of both T1D and T2D
 - Gender (more frequent in males)
- Additional pre-existing conditions which increase the risk of DME:
 - Diabetic retinopathy
 - Obesity (in T1D, and in non-Asian T2D)
 - Previous cataract surgery
 - Nephropathy/microalbuminuria
 - Sleep apnoea
 - Current pregnancy with pre-existing diabetes

2.1 Hyperglycaemia

Hyperglycaemia is a noted cause of DME, and intensive glycaemic control can cut the risk by 50%.



Recommendation

Clinicians should individualise the recommended HbA1c target of 6.5–7.5% (48–58 mmol/mol). An individual's goals should take into account their age; the progression of their disease; their risk of hypoglycaemia; and other factors.

2.2 Hypertension

Elevated blood pressure predisposes a person to develop DME.



Clinical tip

In people with T2D, aggressive blood pressure control (target systolic blood pressure (BP): <120 mmHg) provides modest protection against developing DME. However, once established, DR progresses equally with standard BP control (target systolic BP: <140 mmHg) as with intensive control.

2.3 Dyslipidaemia

The precise role dyslipidaemia plays in DME is unclear. However, fenofibrate can lower retinal inflammation and angiogenesis.



Recommendation

Lifestyle modifications (including weight loss if needed), along with a healthy diet and increased physical activity may improve the lipid profile. Additionally, optimisation of glycaemic control for patients with elevated triglyceride levels (≥ 150 mg/dL [1.7 mmol/L]) and/or low high-density lipoprotein (HDL) cholesterol (<40 mg/dL [1.0 mmol/L] for men, <50 mg/dL [1.3 mmol/L] for women) should be encouraged.

2.4 Duration of diabetes

While everyone with diabetes is at risk of developing DME, elevated glycated haemoglobin (HbA1c) (>7%) and longer disease duration confer the most risk.



Recommendation

Early and regular screening for DME and maintenance of HbA1c within the range specified above is recommended.

2.5 Diabetic retinopathy

The presence and severity of DR are both major risk factors associated with DME.



Recommendation

People with diabetes should receive early and regular screening.

2.6 Obesity

A relationship may exist between DME and the person's overweight and obesity status.



Recommendation

A healthy diet, physical activity, and the support needed to achieve and maintain a >5% decrease in weight should be encouraged for people with DM who are overweight or obese. Diets should be individualised with respect to the person's preferences and dietary needs.

2.7 Cataract surgery

People with diabetes, especially those with DR, may develop DME after cataract surgery. The risk is highest in the first three to six months post-surgery.



Recommendation

Careful follow-up of these patients, especially in the three to six month post-operative period, is needed.

2.8 Sleep apnoea

Patients with sleep apnoea have a significantly higher risk of developing DME.



Recommendation

Careful screening of these patients is necessary. In individuals with both conditions, continuous positive airway pressure (CPAP) therapy can improve vision.

2.9 Pregnancy

Pre-pregnancy hyperglycaemia, especially in the presence of hypertension, may increase the risk of developing DME. The precise cause is not well understood, and various placental hormones may be implicated. It is important that pregnant women with diabetes undergo regular screening to prevent retinopathies such as DME.



Recommendation

Pregnant women with pre-existing diabetes should be regularly screened for DME early in their pregnancy.

Women who are diagnosed with gestational diabetes mellitus (GDM) have the same risk of developing diabetic retinopathy as the general population with diabetes. Therefore, the population with GDM, barring further complications, does not require routine eye examinations during pregnancy.

References

1. Fullerton B, Jeitler K, Seitz M, *et al.* Intensive glucose control versus conventional glucose control for type 1 diabetes mellitus. *Cochrane Database Syst Rev.* 2014 Feb 14;(2):CD009122.
2. Lee R, Wong TY, Sabanayagam C. Epidemiology of diabetic retinopathy, diabetic macular edema and related vision loss. *Eye Vis (Lond).* 2015 Sep 30;2:17.
3. Chew EY, Ambrosius WT, Davis MD, *et al.* ACCORD Study Group, ACCORD Eye Study Group. Effects of medical therapies on retinopathy progression in type 2 diabetes. *N Engl J Med.* 2010 Jul 15;363(3):233–44.
4. Chen Y, Hu Y, Lin M, *et al.* Therapeutic effects of PPAR α agonists on diabetic retinopathy in type 1 diabetes models. *Diabetes.* 2013 Jan;62(1):261–72.
5. American Diabetes Association. *Diabetes Care* 2019 Jan; 42(Supplement1):S103–S123.
6. Ding J, Wong TY. Current epidemiology of diabetic retinopathy and diabetic macular edema. *Curr Diab Rep.* 2012 Aug;12(4):346–54.
7. Kim SJ, Equi R, Bressler NM. Analysis of macular edema after cataract surgery in patients with diabetes using optical coherence tomography. *Ophthalmology.* 2007 May;114(5):881–9.
8. Mason RH, West SD, Kiire CA, *et al.* High prevalence of sleep disordered breathing in patients with diabetic macular edema. *Retina.* 2012 Oct;32(9):1791–8.
9. Mason RH, Kiire CA, Groves DC, *et al.* Visual improvement following continuous positive airway pressure therapy in diabetic subjects with clinically significant macular oedema and obstructive sleep apnoea: proof of principle study. *Respiration.* 2012;84(4):275–82.
10. Rosenn B, Miodovnik M, Kranias G, *et al.* Progression of diabetic retinopathy in pregnancy: association with hypertension in pregnancy. *Am J Obstet Gynecol.* 1992 Apr;166(4):1214–8.
11. Ringholm L, Vestgaard M, Laugesen C, Juul A, Daam P, Mathiesen E. Pregnancy-induced increase in circulating IGF-1 is associated with progression of diabetic retinopathy in women with type 1 diabetes. *Growth hormone & IGF Research.* 2011 Feb;21(1):25–30.
12. Fong D, Aiello L, Gardner T, King G, Blankenship G, Cavallerano J, Ferris III F, Klein R. Retinopathy in Diabetes. *Diabetes Care.* 2004 Jan; 27(suppl 1): s84–s87.

3. Screening for DME

Recommended examination methods include:

- Recording the person’s medical history, with reference to:
 - Blood glucose
 - Blood pressure
 - Lipids
 - Eye screening
- Slit-lamp evaluation of the retina
- Serial fundus photos

Non-mydriatic cameras are commonly used for screening programmes. If the pupils of the screened population are not being dilated, capturing a single macular-centred field is usually the method of choice. Contraction of the pupil following the camera flash means it is typically only possible to acquire one good quality image. Conversely, if the pupils of the screened population are dilated, two fields (one macular-centred and one disc-centred) are typically obtained.

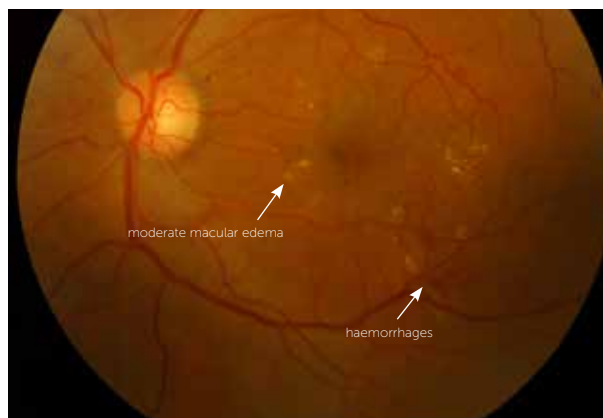


Figure 3. Moderate non-proliferative diabetic retinopathy with moderate macular edema

3.1 Retinal examination

In order to carry out the retinal examination, the examiner should be appropriately trained to:

- Perform ophthalmoscopy or retinal photography
- Assess retinal photographs for the degree of DR

Table 1. Timing of initial and ongoing eye examinations for people with diabetes

Eye Examination	Type 1 diabetes	Type 2 diabetes	Gestational diabetes
Initial examination	<ul style="list-style-type: none"> • Initiate within five years after the diagnosis of diabetes • If date of onset unknown, assume that the duration of diabetes is more than five years • Children: five years after diagnosis or at puberty, whichever is the earlier 	Initiate as soon as possible after diagnosis of diabetes	Conduct on diagnosis of gestational diabetes
Ongoing examinations	<ul style="list-style-type: none"> • Conduct regular examination every one to two years if no abnormality is detected • Once retinopathy is detected, frequency of assessments may need to increase depending on severity of the retinopathy and level of control of systemic risk factors. (See Table 5 Referral criteria for people with type 1 diabetes and type 2 diabetes) 		No need for further examination if diabetes resolves after delivery

Table 2. Referral criteria for people with type 1 diabetes and type 2 diabetes

Condition	Urgent referral as soon as possible	Referral within four months	Referral within six months	No referral	Repeat examination within one year	Repeat examination in one to two years
Sudden severe vision loss	●					
Retinal tear and/or detachment	●					
Proliferative diabetic retinopathy	●					
Severe DME	●					
Unexplained gradual worsening of vision		●				
Visual acuity below 6/12 (20/40)		●				
Symptomatic vision complaints		●				
Unexplained retinal findings		●				
Visual acuity cannot be obtained		●				
Retinal examination cannot be obtained		●				
Previous laser or anti-VEGF treatment		●				
Glaucoma		●				
Cataract		●				
Inability to visualise fundus		●				
Severe non-proliferative diabetic retinopathy		●				
DME without centre involvement		●				
Moderate non-proliferative diabetic retinopathy (no DME)			●			
Mild non-proliferative diabetic retinopathy				●	●	
No apparent diabetic retinopathy				●		●

3.2 Examination method

The retinal examination usually includes one of the following two elements:

1. Direct or indirect ophthalmoscopy or slit-lamp biomicroscopic examination of the retina
2. Retinal (fundus) photography, including:
 - 30° to wide field; or
 - Monophotography; or
 - Stereophotography; or
 - Dilated or undilated photography

Consideration for low-/intermediate resource settings:

Optimally, a screening examination would include:

- Complete ophthalmic examination with refracted visual acuity
- Pupil dilation; and
- State-of-the-art retinal imaging

In low-/intermediate resource settings, the minimum examination components to assure appropriate referral should include:

1. A screening visual acuity examination (pupil dilation, if carried out, should precede vision testing); and
2. A retinal examination adequate for DR classification

In people with no retinopathy, a one- to two-year screening interval may suffice. However, a positive retinopathy diagnosis warrants yearly or more frequent screening.

Table 3: Available assessment instruments and their advantages and disadvantages

Technique	Recommendation	Comments
Direct ophthalmoscopy	<ul style="list-style-type: none"> • Core for management • Pupils must be dilated 	<p>Advantages</p> <ul style="list-style-type: none"> • Mobile • Inexpensive <p>Disadvantages</p> <ul style="list-style-type: none"> • Requires pupil dilation • Small field • Low sensitivity: even with a trained practitioner and red free illumination, small microvascular abnormalities may be difficult to detect • Less effective than slit-lamp biomicroscopy through dilated pupils • No ability to retrospectively audit
Indirect ophthalmoscopy	<ul style="list-style-type: none"> • Core for management • Pupils must be dilated 	<p>Advantages</p> <ul style="list-style-type: none"> • Mobile • Large field • Relatively inexpensive <p>Disadvantages</p> <ul style="list-style-type: none"> • Requires pupil dilation • Even with a trained practitioner and red free illumination, small microvascular abnormalities may be difficult to detect • Less effective than slit-lamp biomicroscopy through dilated pupils • No ability to retrospectively audit
Slit-lamp biomicroscopy	<ul style="list-style-type: none"> • Core for management 	<p>Advantages</p> <ul style="list-style-type: none"> • Large field <p>Disadvantages</p> <ul style="list-style-type: none"> • Requires pupil dilation • Immobile • Requires special lenses • No ability to retrospectively audit

Technique	Recommendation	Comments
Non-mydriatic retinal photography	<ul style="list-style-type: none"> Optional for screening and management 	<p>Advantages</p> <ul style="list-style-type: none"> Large field Can be used by non-medically trained staff No dilation required in 80–90% of cases Some are portable – can be transported to the community in mobile units Can be linked to computers and images can be stored for the long term Allows objective comparison of the same person, or between different groups of people, examined at different times or by different professionals Can be used as a patient education tool, giving immediacy and personal relevance Readily recalled for evaluation of screener performance and audit of grading Auditable <p>Disadvantages</p> <ul style="list-style-type: none"> Relatively expensive A dark space is required for maximum pupil dilation
Non-mydriatic retinal photography used with mydriasis	<ul style="list-style-type: none"> Optional for screening and management 	<p>Advantages</p> <ul style="list-style-type: none"> As above except pupils are dilated for better quality photos <p>Disadvantages</p> <ul style="list-style-type: none"> As above Requires pupil dilation
Mydriatic retinal photography (conventional fundus camera)	<ul style="list-style-type: none"> Optional for screening and management 	<p>Advantages</p> <ul style="list-style-type: none"> Large field <p>Disadvantages</p> <ul style="list-style-type: none"> Requires pupil dilation Expensive Bright flash constricts the pupil for a long time
Fluorescein angiography	<ul style="list-style-type: none"> Not recommended for screening and optional for management 	<p>Advantages</p> <ul style="list-style-type: none"> Only method of assessing capillary circulation <p>Disadvantages</p> <ul style="list-style-type: none"> Invasive and needs general health status assessment Expensive Dilatation needed. Cannot be used by non-medically trained staff
OCT	<ul style="list-style-type: none"> Optional for screening and management 	<p>Advantages</p> <ul style="list-style-type: none"> One of the best ways to assess macular edema (retinal thickening and intraretinal edema) <p>Disadvantages</p> <ul style="list-style-type: none"> Expensive Dilatation needed Cannot be used by non-medically trained staff

3.3 When to refer to an ophthalmologist

The recommendations in the ICO Guidelines for Diabetic Eye Care (published by the International Council of Ophthalmology), are to refer if:

- Visual acuity is below 6/12 (20/40) or the person has symptomatic vision complaints
- Visual acuity or retinal examination cannot be obtained at the screening examination

Other situations requiring follow-up include:

- Patients with an inadequate retinal assessment
- Patients with an unexplained loss of visual acuity
- Women with T1D or T2D, who should be asked if they are or could be pregnant

Women who are pregnant and have hyperglycaemia may also require further follow-up.

3.4 Re-examination and referral recommendations

The following re-examination and referral recommendations are based on international classifications of diabetic macular edema.

For high resource settings:

Classification	Re-examination	Referral to ophthalmologist
Non-central-involved DME	3 months	Referral required
Central-involved DME	1 month	Referral required

For low-/intermediate resource settings:

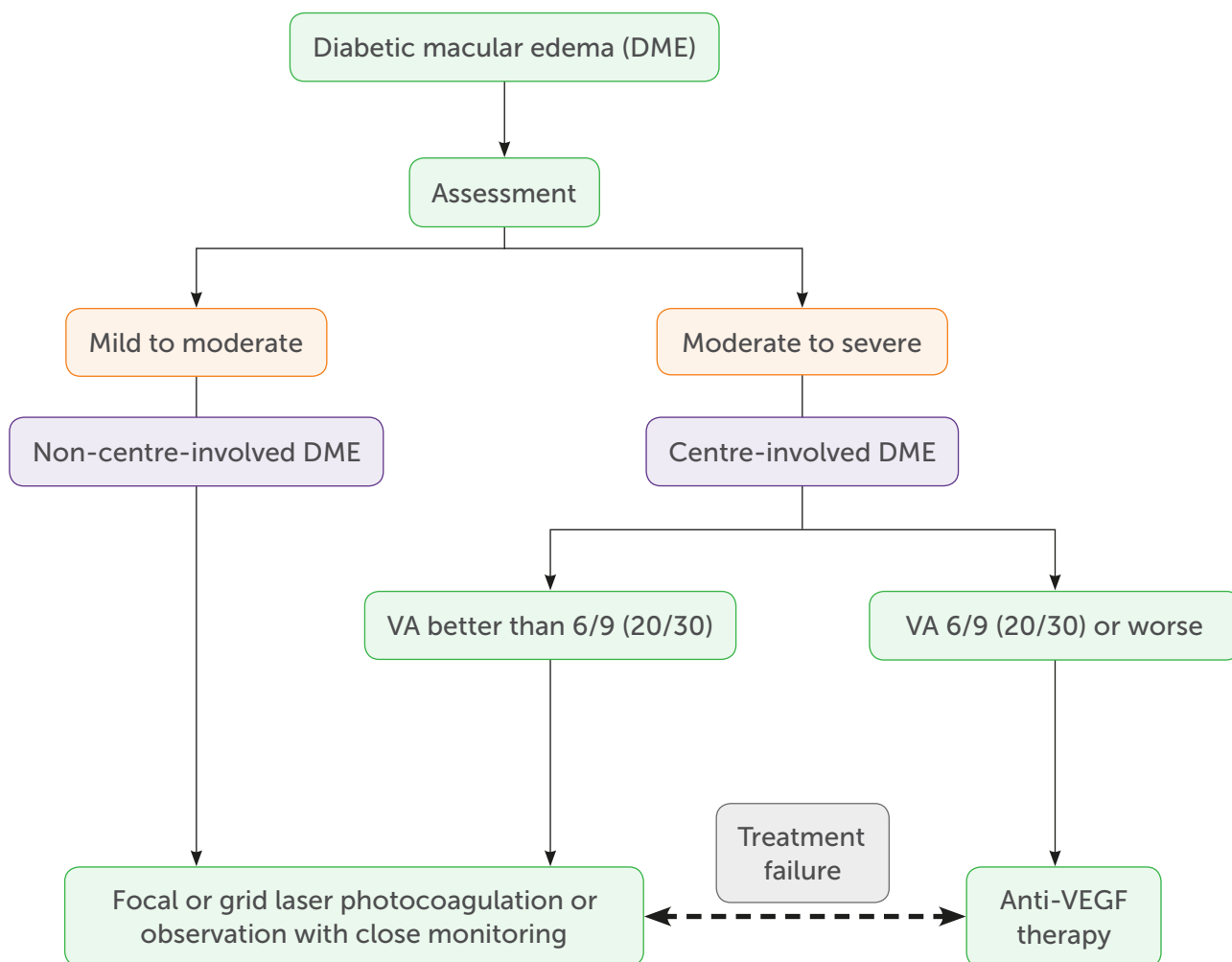
Classification	Re-examination or subsequent screening schedule	Referral to ophthalmologist
Non-central-involved DME	3 months	Referral not required but recommended if laser resources are available
Central-involved DME	1 month	Referral required

People with diabetes who are not experiencing visual problems may already have advanced stages of DME. Therefore, it is important that they undergo screening.

References

1. Wong TY, Sun J, Kawasaki R, *et al.* Guidelines on Diabetic Eye Care: The International Council of Ophthalmology Recommendations for Screening, Follow-up, Referral, and Treatment Based on Resource Settings. *Ophthalmology*. 2018 Oct;125(10):1608–1622.
2. Klein R, Knudtson MD, Lee KE, *et al.* The Wisconsin Epidemiologic Study of Diabetic Retinopathy XXIII: the twenty-five-year incidence of macular edema in persons with type 1 diabetes. *Ophthalmology*. 2009 Mar;116(3):497–503.
3. International Diabetes Federation. Diabetes Eye Health: A guide for health professionals. Brussels, Belgium: International Diabetes Federation.
<https://www.idf.org/our-activities/care-prevention/eye-health.html>
4. Tan GS, Cheung N, Simó R, *et al.* Diabetic macular oedema. *Lancet Diabetes Endocrinol*. 2017 Feb;5(2):143–155.
5. International Council of Ophthalmology. Guidelines for Diabetic Eye Care. Updated 2017.
<http://www.icoph.org/downloads/ICOGuidelinesforDiabeticEyeCare.pdf>
6. Rafał Muc, Agnieszka Saracen, Jarostaw Pinkas, *et al.* Diabetic macular edema management – international guidelines overview. *Post N Med*. 2017; XXX(03): 151–156.

4. Treatment of DME



As well as the strategies used to manage risk factors for DME, there are four main therapeutic options for treating the condition:

- Laser photocoagulation
 - Intravitreal VEGF inhibitors
 - Intravitreal injections
 - Polytherapy consisting of laser photocoagulation **plus** VEGF, or photocoagulation **plus** intravitreal steroid treatment
- For patients with non-central-involved DME and mild visual impairment, laser photocoagulation and close observation are recommended.
 - For those with central-involved DME and moderate visual impairment, intravitreal

therapy has evolved as the treatment of choice.

- The goals of treatment are to:
 - Prevent blindness
 - Restore impaired vision where possible
 - Prevent further vision loss
 - Improve visual function

Therapies including the intraocular injection of steroids and anti-VEGF agents preserve the retina better than older treatment options, and can be useful in patients for whom conventional therapy is ineffective.

Promising steps are being made towards the development of alternative modes of treatment, including the inhibition of other angiogenic factors; regenerative therapy; and topical therapy.

4.1 Laser photocoagulation

Grid and/or focal laser photocoagulation is effective for stabilising and protecting remaining sight. However, its ability to reverse vision loss is poor. The photocoagulation stops microaneurysms from leaking into the macula, and improves oxygenation.

Recommendations



Diffuse DME

- First-line therapy
 - Monotherapy – intravitreal anti-VEGF or corticosteroids
 - Polytherapy – macular laser and intravitreal therapy
 - Widely used
 - Shown to reduce the number of injections needed
 - Patients for whom intravitreal agents are ineffective
 - Use conventional grid laser photocoagulation

Focal or multifocal DME

- First-line therapy
 - Laser photocoagulation, if:
 - Angiography has detected microaneurysms
 - Only a few fluorescein leakage points are detected and they are more than 500 µm from the centre of the macula
 - The eye has not undergone laser treatment in the past with ineffective results

Potential side effects of laser photocoagulation:

- Foveal burns
- Deficiencies in the central visual field
- Changes in sensitivity to contrast
- Impaired night vision
- Retinal fibrosis
- Choroidal scarring and neovascularisation

4.2 Intravitreal injections

Intravitreal injections have evolved to become the preferred strategy for treating DME as an alternative to laser photocoagulation. They include:

- Anti-VEGF therapies
 - Ranibizumab
 - Bevacizumab
 - Aflibercept
- Corticosteroids/vitreous inserts (sustained delivery)
 - Triamcinolone acetonide
 - Dexamethasone
 - Fluocinolone acetonide

Anti-VEGF therapy

- First-line therapy for central-involved DME
- Administered via intravitreal injections under topical anaesthesia
- Ranibizumab
 - Preserves vision
 - Improves long-term vision outcomes
 - Lower cost
- Aflibercept
 - Offers most vision improvement in patients with baseline visual acuity of 20/50 or worse

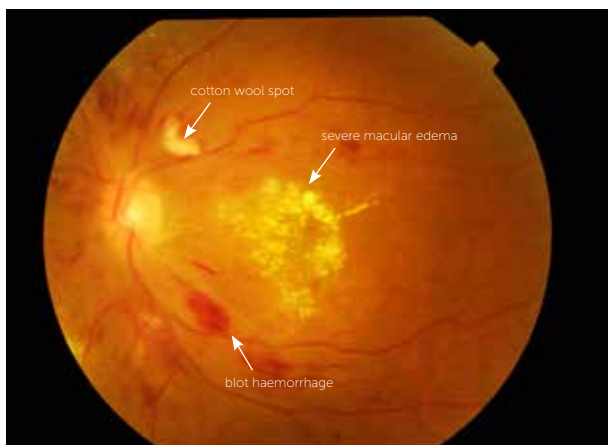


Figure 4. Severe non-proliferative diabetic retinopathy with severe diabetic macular edema

These medications are superior to laser treatment in slowing the advance of DR.

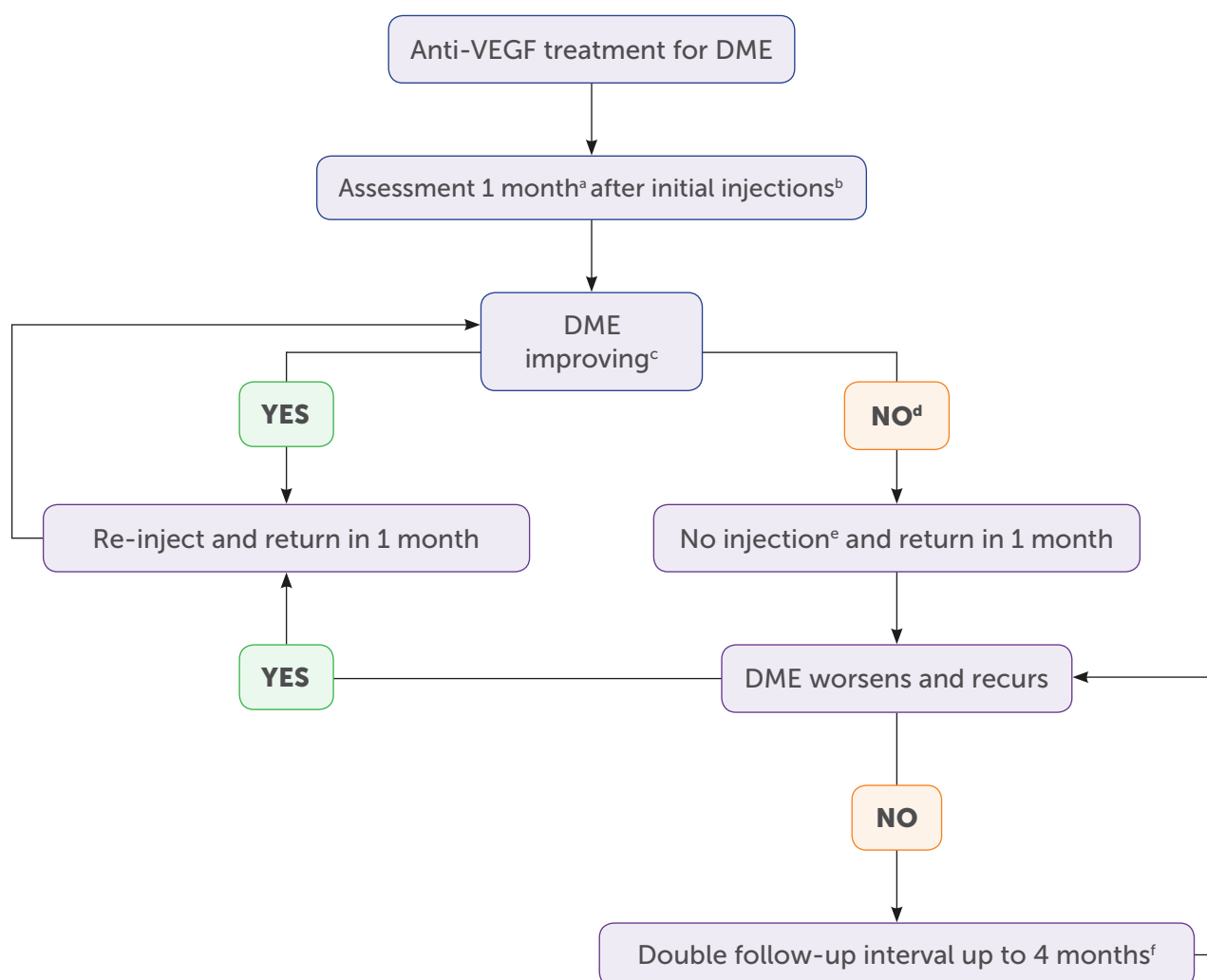
In patients with both PDR and DME, monotherapy has demonstrated positive outcomes and superior vision improvement compared with laser or combination therapy.



Clinical tip

Intravitreal administration of anti-VEGF therapy is generally considered safe, and ocular complications are rare.

Anti-VEGF treatment decision tree based on the DRCR.net re-treatment and follow-up schedule



- a** In the DRCR.net study, 4-week, not 1-month, intervals were used.
- b** The DRCR.net study required 4 injections of intravitreal ranibizumab every 4 weeks initially; it is not known whether a different number of injections initially would have worked as well. DRCR.net also required 2 additional injections at months 5 and 6 if edema persisted and success had not been met, even in the absence of improvement.
- c** Relevant details from the DRCR.net study: 1) DRCR.net "improvement" on Zeiss Stratus OCT >10% decrease in central subfield thickness; 2) Even if no longer improving on OCT, injections continued if VA "improvement" (unless 6/6 or better); 3) VA improvement defined as 5 or more letter increase on Electronic ETDRS Visual Acuity Test.
- d** In the DRCR.net study, if focal/grid laser was deferred at baseline, it was added at or after 24 weeks if edema still present and OCT central subfield and vision no longer improving.
- e** In the DRCR.net study, all patients received at least 4 injections 4 weeks apart. The decision to re-inject was at investigator discretion, starting at 16 weeks for "success", defined as VA better than 6/6 or OCT central subfield <250µm. Starting at 24 weeks, re-injection was also at investigator discretion if no improvement in OCT central subfield or vision.
- f** The DRCR.net study continued to follow-up every 4 weeks through the 52-week visit and did not permit extension of follow-up until after the 52 week visit. If injection was withheld due to no improvement or success at 3 consecutive visits following the week 52 visit, follow-up interval was doubled to 8 weeks and then again to 16 weeks if still no change.

Since new intravitreal therapies may be costlier for national health systems, a cost-benefit analysis is recommended in settings with limited resources.

Corticosteroid therapy/vitreous inserts (sustained delivery)

- Second-line treatment for patients for whom anti-VEGF therapy is ineffective
- Corticosteroids have powerful anti-inflammatory and anti-edematous effects
- Corticosteroid agents are commercially available for intravitreal use as:
 - Triamcinolone acetonide (TA)
 - Dexamethasone implant (Ozurdex®)
 - Fluocinolone acetonide (FAC) (Iluvien®)



Recommendations

- TA has the side effect of causing the formation of cataracts
- Following intensive anti-VEGF treatment, patients who have had previous cardiovascular events are at greater risk of death and cardiovascular accidents. Corticosteroids are the preferred treatment option for these patients
- Sustained-release corticosteroids provide an option for patients for whom the monthly frequency of anti-VEGF treatments would be a substantial burden
- Steroid treatment is preferred for pseudophakic patients
- Phakic patients should be informed and followed up for the possibility of cataract formation or progression

4.3 Polytherapy

- Polytherapy involving laser and anti-VEGF therapy can provide effective results
- A combination of steroids and anti-VEGF therapies together has also shown a favourable response
- Non-central-involved DME shows positive results from focal/grid laser photocoagulation
- Treatment with other therapeutic agents (e.g., anti-inflammatory agents or corticosteroids) may yield improvements in visual outcome
- Polytherapy involving laser and anti-VEGF therapy can provide effective results

4.4 Surgical approaches

- Vitrectomy may help remove advanced glycation end products (AGEs) from the vitreoretinal interface or remove abnormally adherent vitreous that could induce DME
- AGEs are caused by primary hyperglycaemia

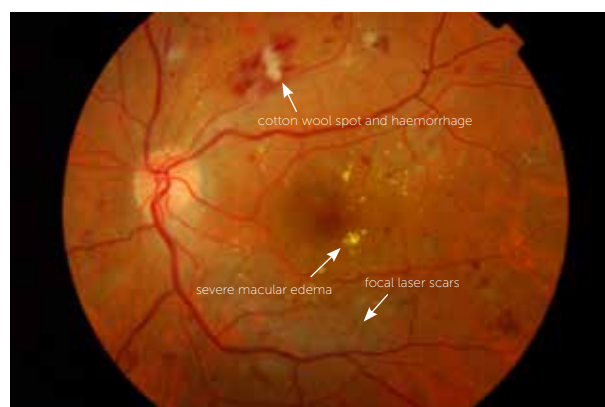

Figure 5. Persistent diabetic macular edema after focal laser treatment.

References

1. Wong, T, Sun J, Kawasaki R, *et al.* Guidelines on Diabetic Eye Care: The International Council of Ophthalmology Recommendations for Screening, Follow-up, Referral, and Treatment Based on Resource Settings. *Ophthalmology* 2018;125:1608–1622.
2. Strioph GG, Hart WM Jr, Olk RJ. Modified grid laser photocoagulation for diabetic macular edema. The effect on the central visual field. *Ophthalmology*. 1988 Dec;95(12):1673–9.
3. Lee CM, Olk RJ. Modified grid laser photocoagulation for diffuse diabetic macular edema. Long-term visual results. *Ophthalmology*. 1991 Oct;98(10):1594–602.
4. Schmidt-Erfurth U, Lang GE, *et al.* Three-year outcomes of individualized ranibizumab treatment in patients with diabetic macular edema: the RESTORE extension study. *Ophthalmology*. 2014 May;121(5):1045–53.
5. Elman MJ, Qin H, Aiello LP, *et al.* Intravitreal ranibizumab for diabetic macular edema with prompt versus deferred laser treatment: three-year randomized trial results. *Ophthalmology*. 2012 Nov;119(11):2312–8.
6. Do DV, Nguyen QD, Khwaja AA, *et al.* Ranibizumab for edema of the macula in diabetes study: 3-year outcomes and the need for prolonged frequent treatment. *JAMA Ophthalmol*. 2013 Feb;131(2):139–45.
7. Aiello LM. Perspectives on diabetic retinopathy. *Am J Ophthalmol*. 2003 Jul;136(1):122–35.
8. Focal photocoagulation treatment of diabetic macular edema. Relationship of treatment effect to fluorescein angiographic and other retinal characteristics at baseline: ETDRS report no. 19. Early Treatment Diabetic Retinopathy Study Research Group. *Arch Ophthalmol*. 1995 Sep;113(9):1144–55.
9. Nguyen QD, Brown DM, Marcus DM, *et al.* Ranibizumab for diabetic macular edema: results from 2 phase III randomized trials: RISE and RIDE. *Ophthalmology*. 2012 Apr;119(4):789–801.
10. Cheung N, Wong IY, Wong TY. Ocular anti-VEGF therapy for diabetic retinopathy: overview of clinical efficacy and evolving applications. *Diabetes Care*. 2014 Apr;37(4):900–5.
11. Heier JS, Korobelnik JF, Brown DM, *et al.* Intravitreal Aflibercept for Diabetic Macular Edema: 148-Week Results from the VISTA and VIVID Studies. *Ophthalmology*. 2016 Nov;123(11):2376–2385.
12. Brown DM, Schmidt-Erfurth U, Do DV, *et al.* Intravitreal Aflibercept for Diabetic Macular Edema: 100-Week Results From the VISTA and VIVID Studies. *Ophthalmology*. 2015 Oct;122(10):2044–52.
13. Bressler SB, Qin H, Melia M, *et al.* Diabetic Retinopathy Clinical Research Network. Exploratory analysis of the effect of intravitreal ranibizumab or triamcinolone on worsening of diabetic retinopathy in a randomized clinical trial. *JAMA ophthalmology*. 2013 Aug;131(8):1033–40.
14. Gross JG, Glassman AR, Liu D, *et al.* Five-Year Outcomes of Panretinal Photocoagulation vs Intravitreal Ranibizumab for Proliferative Diabetic Retinopathy: A Randomized Clinical Trial. *JAMA ophthalmology*. 2018 Oct1;136(10):1138–1148.
15. Sivaprasad S, Prevost AT, Vasconcelos JC, *et al.* Clinical efficacy of intravitreal aflibercept versus panretinal photocoagulation for best corrected visual acuity in patients with proliferative diabetic retinopathy at 52 weeks (CLARITY): a multicentre, single-blinded, randomised, controlled, phase 2b, non-inferiority trial. *Lancet*. 2017 Jun 3;389(10085):2193–2203.
16. International Council of Ophthalmology. Guidelines for Diabetic Eye Care. Updated 2017.
17. Whitcup SM, Cidlowski JA, Csaky KG, *et al.* Pharmacology of corticosteroids for diabetic macular edema. *Invest Ophthalmol Vis Sci*. 2018 Jan 1;59(1):1–12.
18. Jousseaume AM, Murata T, Tsujikawa A, *et al.* Leukocyte-mediated endothelial cell injury and death in the diabetic retina. *Am J Pathol*. 2001 Jan;158(1):147–52.
19. Stitt A. AGEs and Diabetic Retinopathy. *Investigative Ophthalmology & Visual Science* October 2010, Vol.51, 4867–4874. doi:10.1167/iovs.10-5881.

5. Systemic management of DME

Systemic therapy for DME aims to prevent complications and slow the rate of progression by targeting related modifiable conditions such as hyperglycaemia, hypertension and dyslipidaemia. Optimisation of glycaemic levels, blood pressure, and blood lipids remain key approaches for retarding the progression of DR and DME.

Glycaemic control

- Intensive glycaemic control provides important and enduring protection against DME
- The effectiveness of conservative blood sugar control diminishes once complications have developed; in older people; or in those with macrovascular disease.
- People who are prescribed glitazones demonstrate an increased rate of fluid retention and thus DME. The latter resolves upon the cessation of glitazone use. Therefore, treatment considerations should include the edema associated with these medications, especially in those already diagnosed with peripheral edema.

Recommendations

An HbA1c target of 6.5%–7.5% (48–58 mmol/mol) with few hypoglycaemic episodes is generally acceptable. However, clinicians should consider relevant factors when establishing targets:

- Age
- Disease duration (longer than 10 years)
- Progression of the condition
- Hypoglycaemia risk
- Other factors

Hypertension

- Optimal control of hypertension is an important means of preventing and mitigating the progression of DME.

Clinical tip

Standard control of blood pressure results in similar protection to aggressive control measures.

Lipid management

The presence of hard exudates and vision loss are associated with hyperlipidaemia, which can be treated with fenofibrate.

- Fenofibrate reduces the need for focal laser therapy or surgery, especially when combined with simvastatin
- In people diagnosed with DME, fenofibrate may reduce the thickness of the macula. It significantly lowers the risk of progression of retinopathy

Recommendation

Fenofibrate treatment is strongly recommended for DR cases.

Additional considerations

- Anaemia promotes the advancement of DME through the exacerbation of hypoxia in the retina. Growth factors such as VEGF subsequently develop as well. As a result, anaemia is a contributory risk factor for DME
- Clinicians are strongly encouraged to assess haematocrit levels, especially in people diagnosed with sight-threatening retinopathy, PDR and central-involved DME.
- People diagnosed with anaemia and renal impairment may experience improved visual acuity from the intravenous administration of erythropoietin.

References

1. Fullerton B, Jeitler K, Seitz M, et al. Intensive glucose control versus conventional glucose control for type 1 diabetes mellitus. *Cochrane Database Syst Rev*. 2014 Feb 14;(2):CD009122.
2. Ryan EH Jr, Han DP, Ramsay RC, et al. Diabetic macular edema associated with glitazone use. *Retina*. 2006 May-Jun;26(5):562–70.
3. Tight blood pressure control and risk of macrovascular and microvascular complications in type 2 diabetes: UKPDS 38. UK Prospective Diabetes Study Group. *BMJ*. 1998 Sep 12;317(7160):703–13.
4. Chew EY, Ambrosius WT, Davis MD, et al. ACCORD Study Group, ACCORD Eye Study Group. Effects of medical therapies on retinopathy progression in type 2 diabetes. *N Engl J Med*. 2010 Jul 15;363(3):233–44.
5. McGill J, Bell D, Anemia and the role of erythropoietin in diabetes. *Journal of Diabetes and its Complications*. 2006 Jul–Aug (20)262–272.

6. Patient communication and education

Communicating

- Use words and terms that the person can understand
- Provide information on the possible outcomes of treatment and non-treatment
- Set targets and goals with the patient

Informing and empowering

When discussing treatment options with the patient, health professionals should:

- Describe the benefits of treatment, as well as costs to the patient (for example, financial and social)
- Explain what they will experience during and after their treatment
- Emphasise the importance of continued eye examinations and their anticipated schedule
- Discuss the things the person can do to facilitate the management of their condition
- Explore ways of educating the person living with diabetes, family members and/or caregivers about the need to manage blood sugar levels, blood pressure and cholesterol, as well as the importance of not smoking and avoiding high-impact straining, anaerobic exercise
- Encourage lifestyle modifications

- Provide support for ongoing self-management

Encouraging regular examinations

People may be more likely to attend regular eye examinations if:

- They are educated about the need for regular eye examinations and encouraged to attend, even if their vision is symptom-free
- They are given the opportunity to select the type of appointment reminders they will find most useful
- Their fear of vision loss is acknowledged and discussed, as this concern prevents many people from seeking screening and treatment

Reference

1. International Diabetes Federation. Diabetes Eye Health: A guide for health professionals. Brussels, Belgium: International Diabetes Federation

Abbreviations

AGE	Advanced glycation end products
BP	Blood pressure
BRB	Blood retinal barrier
CSME	Clinically significant macular edema
DME	Diabetic macular edema
DR	Diabetic retinopathy
FA	Fluorescent angiography
FAc	Fluocinolone acetonide
GDM	Gestational diabetes mellitus
HDL	High-density lipoprotein
HbA1c	Glycosylated haemoglobin
IDF	International Diabetes Federation
ICO	International Council of Ophthalmology
OCT	Optical coherence tomography
PDR	Proliferative diabetic retinopathy
T1D	Type 1 diabetes
T2D	Type 2 diabetes
TA	Triamcinolone acetonide
VEGF	Vascular endothelial growth factor



**International
Diabetes
Federation**

166 Chaussée de La Hulpe
B-1170, Brussels | Belgium
Tel +32 (0)2 538 55 11
Fax +32 (0)2 538 51 14
info@idf.org | www.idf.org